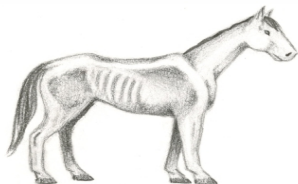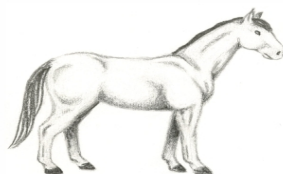


HORSE BODY CONDITION



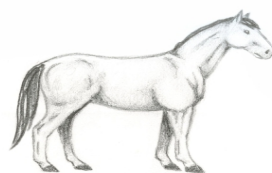
Very Thin: Horse emaciated. Slight fat covering over base of spinous processes, transverse processes of lumbar vertebrae feel rounded. Spinous processes, ribs, tailhead, tuber coxae and ischii prominent. Withers, shoulders, and neck structures faintly discernible.



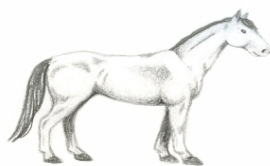
Moderately Fleshy: May have slight crease down back. Fat over ribs feels spongy. Fat around tailhead feels soft. Fat beginning to be deposited along the side of the withers, behind the shoulders and along the sides of the neck.



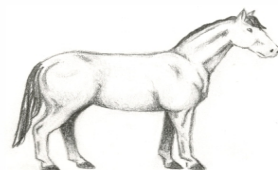
Thin: Fat build up about halfway on spinous processes, transverse processes can not be felt. Slight fat cover over ribs. Spinous processes and ribs easily discernible. Tailhead prominent, but individual vertebrae cannot be visually identified. Tuber coxae appear rounded, but easily discernible. Tuber ischia not distinguishable. Withers, shoulders and neck accentuated.



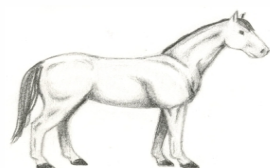Fleshy: May have crease down back. Individual ribs can be felt, but noticeable filling between ribs with fat. Fat around tailhead is soft. Fat deposited along withers, behind shoulders and along neck.



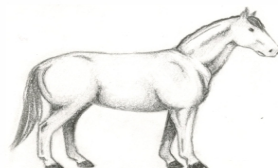Moderately Thin: Negative crease along back. Faint outline of ribs discernible. Tailhead prominence depends on conformation, fat can be felt around it. Tuber coxae not discernible. Withers, shoulders and neck not obviously thin.



Fat: Crease down back. Difficult to feel ribs. Fat around tailhead very soft. Area along withers filled with fat. Area behind shoulder filled with fat. Noticeable thickening of neck. Fat deposited along inner thigh.



Moderate: Back level. Ribs cannot be visually distinguished but can be easily felt. Fat around tailhead beginning to feel spongy. Withers appear rounded over spinous processes. Shoulders and neck blend smoothly into body.



Extremely Fat: Obvious crease down back. Patchy fat appearing over ribs. Bulging fat around tailhead, along withers, behind shoulders and along neck. Fat along inner thighs may rub together. Flank filled with fat.