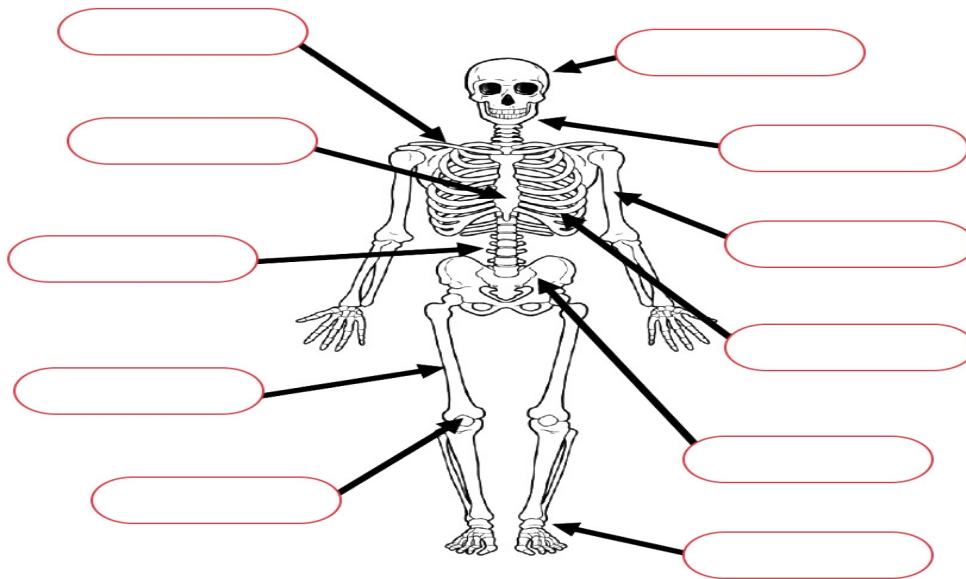


Name: _____

Date: _____

HUMAN SKELETON



Skull

Ribs

Sternum

Jawbone

Spine

Femur

Pelvis

Knee Cap

Collar Bone

Ankle

Humerus