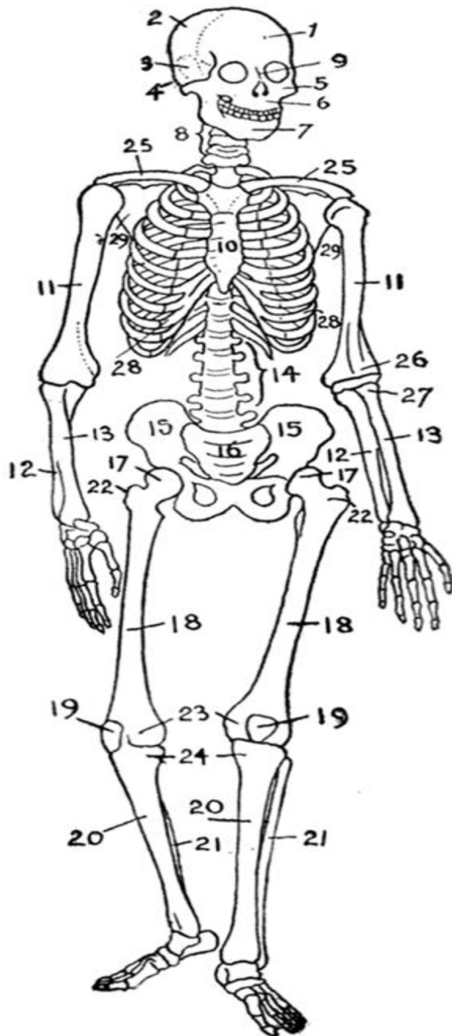


List of Bones of the Human Skeleton

A typical adult human skeleton consists of the following 206 bones. (Numbers in bold refer to the diagram at right.)



In the skull (22):

- Cranial bones:
 - **1. frontal bone**
 - **2. parietal bone (2)**
 - **3. temporal bone (2)**
 - **4. occipital bone**
 - **sphenoid bone**
 - **ethmoid bone**
- Facial bones:
 - **5. zygomatic bone (2)**
 - **6. superior and inferior maxilla**
 - **9. nasal bone (2)**
 - **7. mandible**
 - **palatine bone (2)**
 - **lacrimal bone (2)**
 - **vomer bone**
 - **inferior nasal conchae (2)**

In the middle ears (6):

- malleus (2)
- incus (2)
- stapes (2)

In the throat (1):

- **hyoid bone**

In the shoulder girdle (4):

- **25. clavicle or collarbone (2)**
- **29. scapula or shoulder blade (2)**

In the thorax (25):

- **10. sternum: manubrium, body, xyphoid process**
- **28. ribs (2 x 12): True & False (10-12 Floating)**

In the vertebral column (24):

- **8. cervical vertebrae (7) incl. atlas & axis**
- **14. lumbar vertebrae (5)**
- **thoracic vertebrae (12)**

In the arms (6):

- **11. humerus (2)**
 - **26. condyles of humerus**