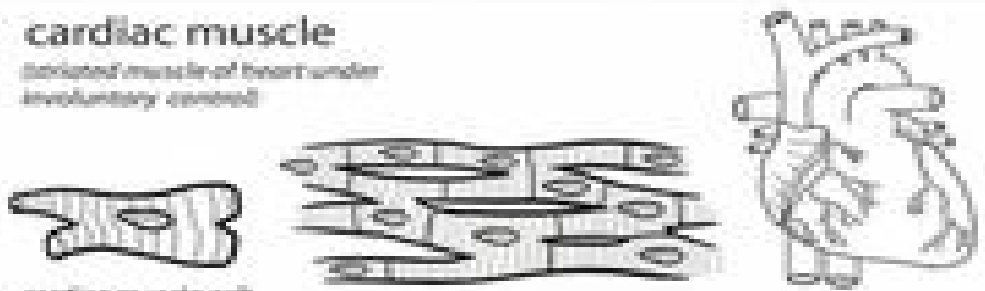


# Muscle

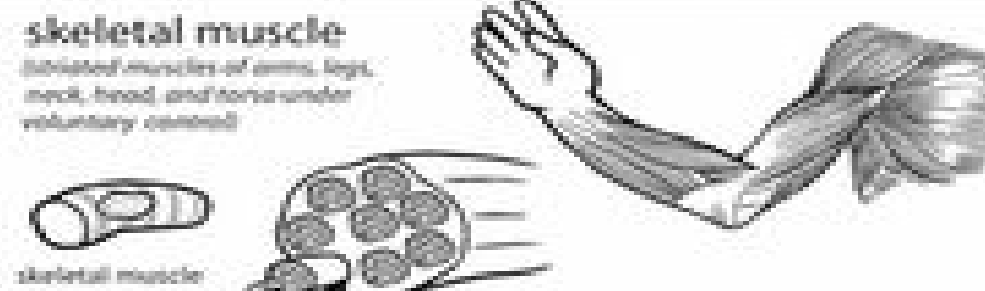
**cardiac muscle**  
(striated muscle of heart under involuntary control)



cardiac muscle cell

This panel illustrates cardiac muscle. On the left is a single cardiac muscle cell, which is branched and striated. In the center is a bundle of cardiac muscle tissue, showing the branching cells and their striations. On the right is a drawing of a human heart, showing its overall shape and major vessels.


**skeletal muscle**  
(striated muscles of arms, legs, neck, head and torso under voluntary control)



skeletal muscle cell

This panel illustrates skeletal muscle. On the left is a single skeletal muscle cell, which is long and cylindrical with a central nucleus. In the center is a bundle of skeletal muscle tissue, showing multiple parallel muscle fibers. On the right is a drawing of a human arm, showing the skeletal muscles of the upper limb.

**smooth muscle**  
(non-striated muscles of the blood vessels, digestive system, respiratory system, urinary tract and reproductive system under involuntary control)



smooth muscle cell

This panel illustrates smooth muscle. On the left is a single smooth muscle cell, which is spindle-shaped and non-striated. In the center is a sheet of smooth muscle tissue, showing the cells arranged in a regular pattern. On the right is a drawing of a human stomach, showing its characteristic shape and the smooth muscle that lines its interior.