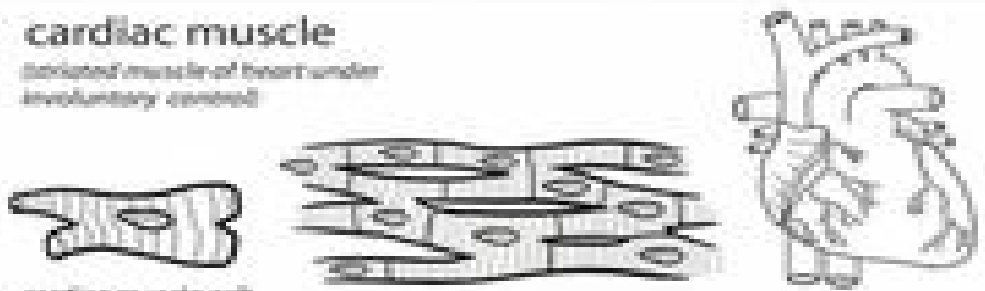


Muscle

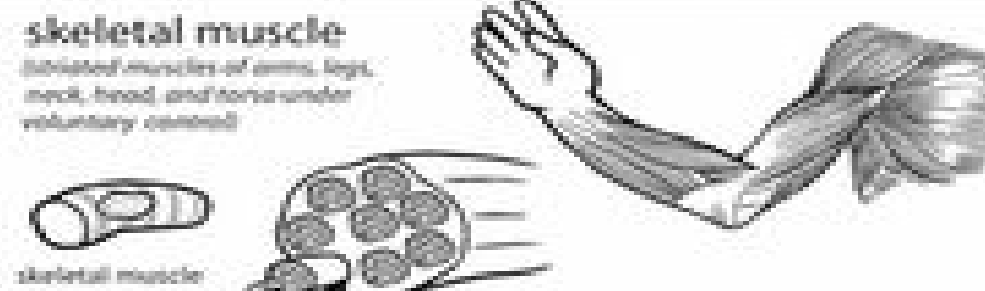
cardiac muscle
(striated muscle of heart under involuntary control)



cardiac muscle cell

This panel illustrates cardiac muscle. On the left is a single cardiac muscle cell, which is branched and striated. In the center is a cross-section of striated muscle tissue showing multiple cells with visible striations and nuclei. On the right is a drawing of a human heart, showing its complex structure and branching vessels.


skeletal muscle
(striated muscles of arms, legs, neck, head and torso under voluntary control)



skeletal muscle cell

This panel illustrates skeletal muscle. On the left is a single skeletal muscle cell, which is long and cylindrical with a central nucleus. In the center is a cross-section of skeletal muscle tissue showing multiple cells with striations and nuclei. On the right is a drawing of a human arm, showing the skeletal structure and the underlying muscle tissue.

smooth muscle
(non-striated muscles of the blood vessels, digestive system, respiratory system, urinary tract and reproductive system under involuntary control)



smooth muscle cell

This panel illustrates smooth muscle. On the left is a single smooth muscle cell, which is spindle-shaped and lacks striations. In the center is a cross-section of smooth muscle tissue showing multiple cells with nuclei. On the right is a drawing of a human stomach, showing its characteristic shape and internal structure.