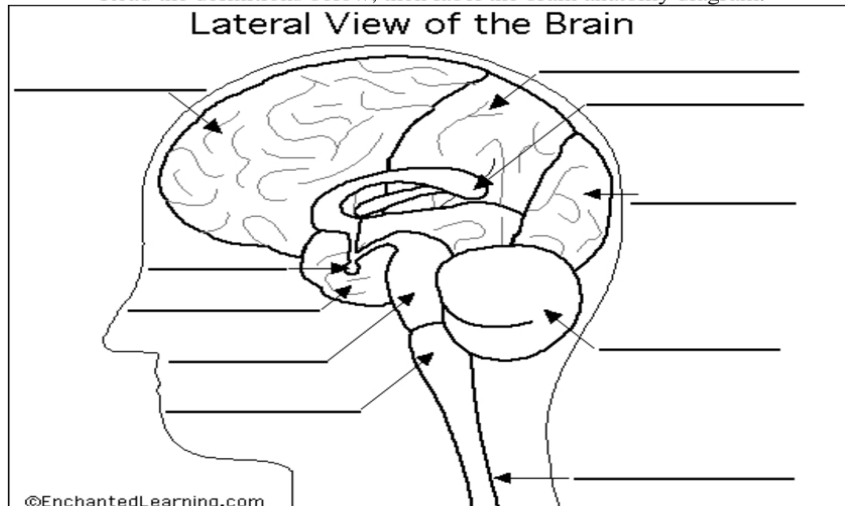


## Label the Brain Anatomy Diagram

[The Brain](#)

Read the definitions below, then label the brain anatomy diagram.



**Cerebellum** - the part of the brain below the back of the cerebrum. It regulates balance, posture, movement, and muscle coordination.

**Corpus Callosum** - a large bundle of nerve fibers that connect the left and right cerebral hemispheres. In the lateral section, it looks a bit like a "C" on its side.

**Frontal Lobe of the Cerebrum** - the top, front regions of each of the cerebral hemispheres. They are used for reasoning, emotions, judgment, and voluntary movement.

**Medulla Oblongata** - the lowest section of the brainstem (at the top end of the spinal cord); it controls automatic functions including heartbeat, breathing, etc.

**Occipital Lobe of the Cerebrum** - the region at the back of each cerebral hemisphere that contains the centers of vision and reading ability (located at the back of the head).

**Parietal Lobe of the Cerebrum** - the middle lobe of each cerebral hemisphere between the frontal and occipital lobes; it contains important sensory centers (located at the upper rear of the head).

**Pituitary Gland** - a gland attached to the base of the brain (located between the Pons and the Corpus Callosum) that secretes hormones.

**Pons** - the part of the brainstem that joins the hemispheres of the cerebellum and connects the cerebrum with the cerebellum. It is located just above the Medulla Oblongata.

**Spinal Cord** - a thick bundle of nerve fibers that runs from the base of the brain to the hip area, running through the spine (vertebrae).

**Temporal Lobe of the Cerebrum** - the region at the lower side of each cerebral hemisphere; contains centers of hearing and memory (located at the sides of the head).