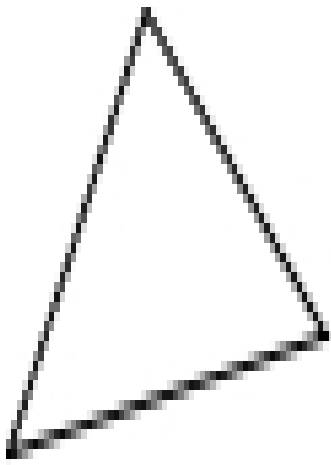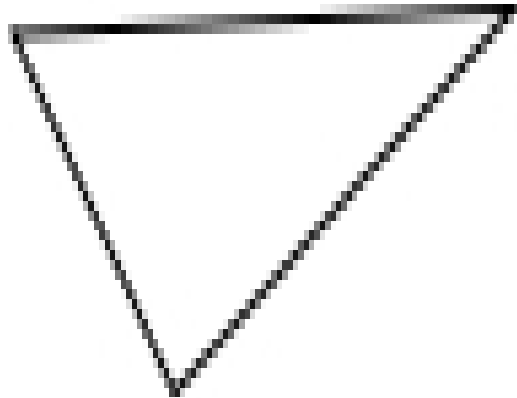



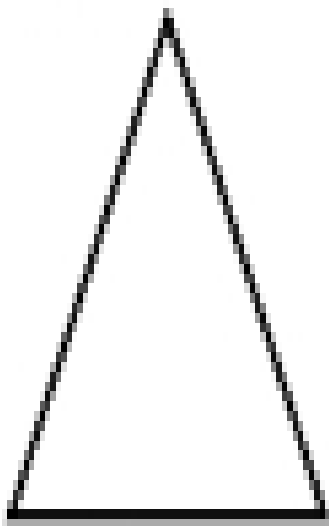
Acute




Obtuse



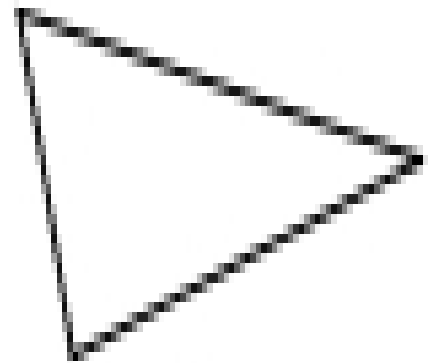
Right



Equilateral



Isosceles



Scalene