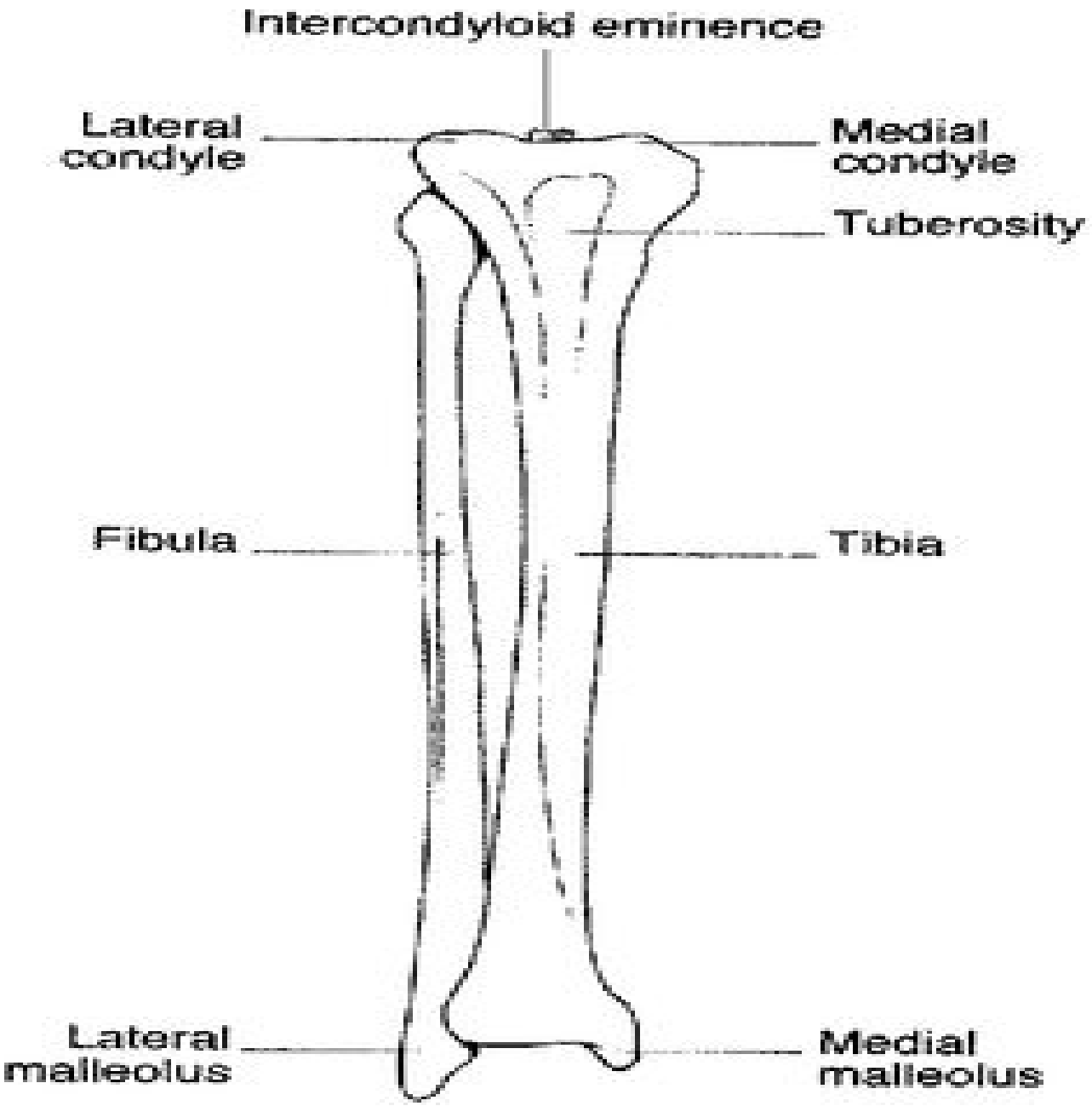
Intercondyloid eminence
Lateral condyle
Medial condyle
Tuberosity
Fibula
Tibia
Lateral malleolus
Medial malleolus