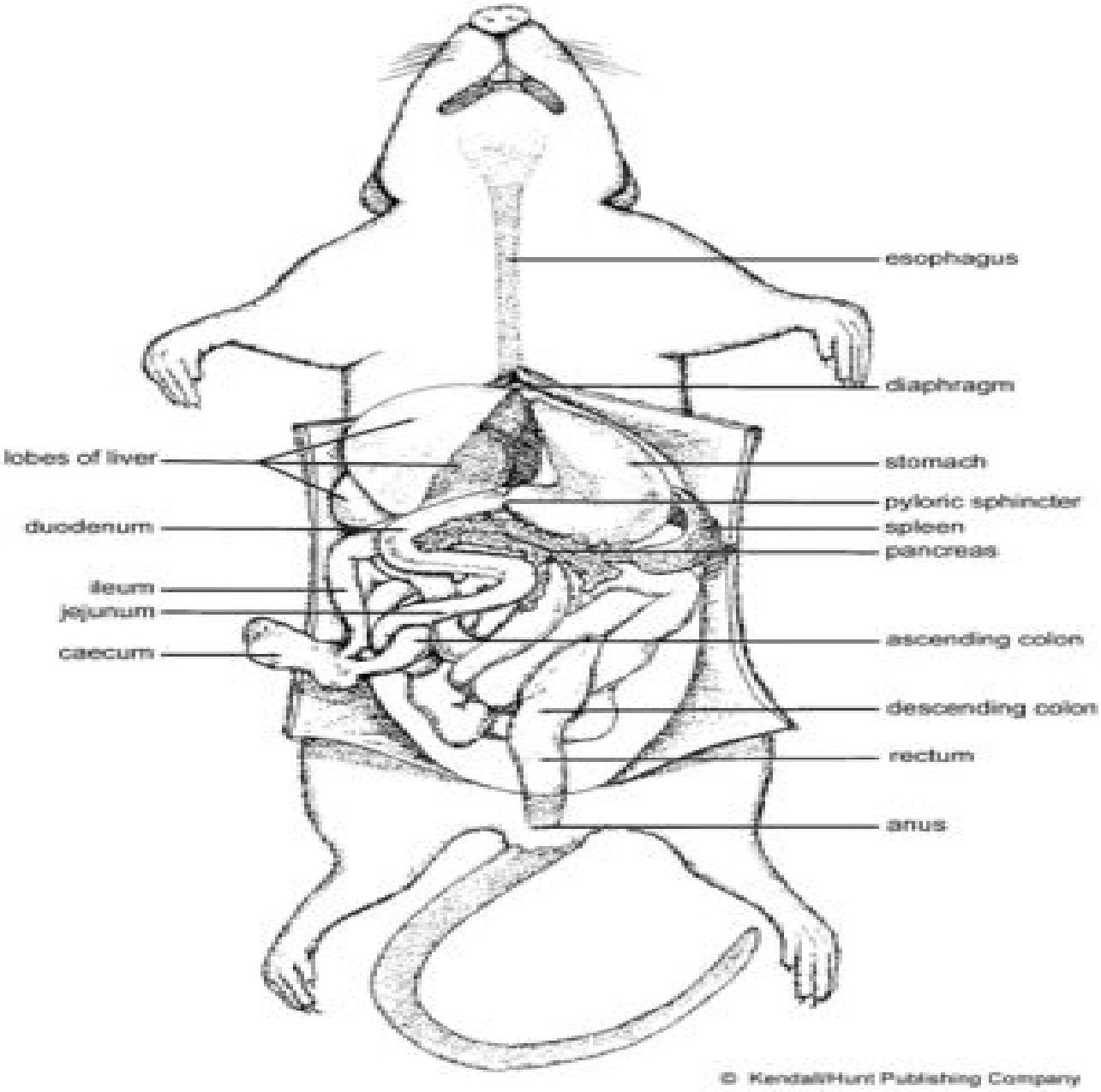
esophagus
diaphragm
lobes of liver
stomach
pyloric sphincter
duodenum
spleen
pancreas
ileum
jejunum
ascending colon
caecum
descending colon
rectum
anus
© Kendall/Hunt Publishing Company