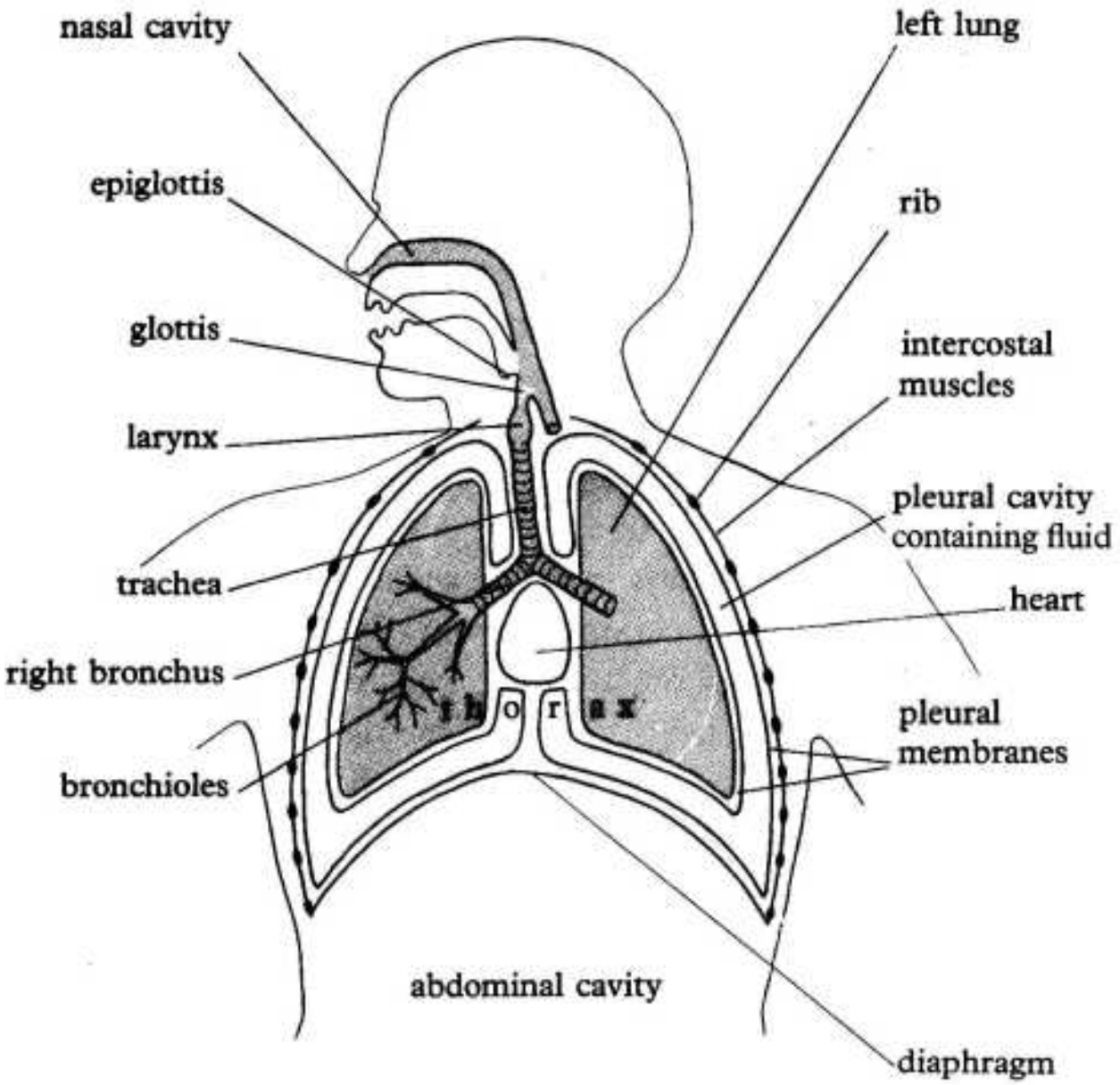
nasal cavity
epiglottis
glottis
larynx
trachea
right bronchus
bronchioles
left lung
rib
intercostal muscles
pleural cavity containing fluid
heart
pleural membranes
abdominal cavity
diaphragm
t h o r a x