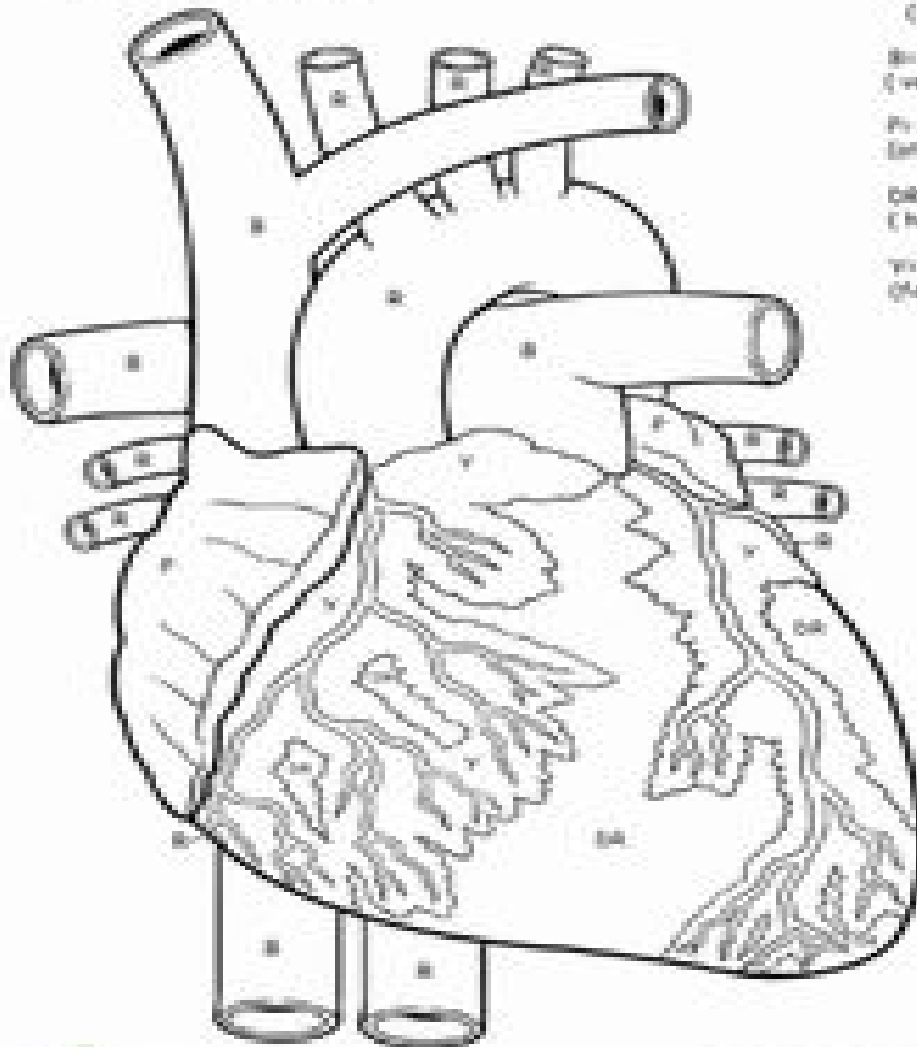


The Heart



Rr bright red
(arteries)

Bb blue
(veins)

Pp dark purple
(tricuspid)

Dd dark red
(heart muscle)

Yy yellow
(fat)