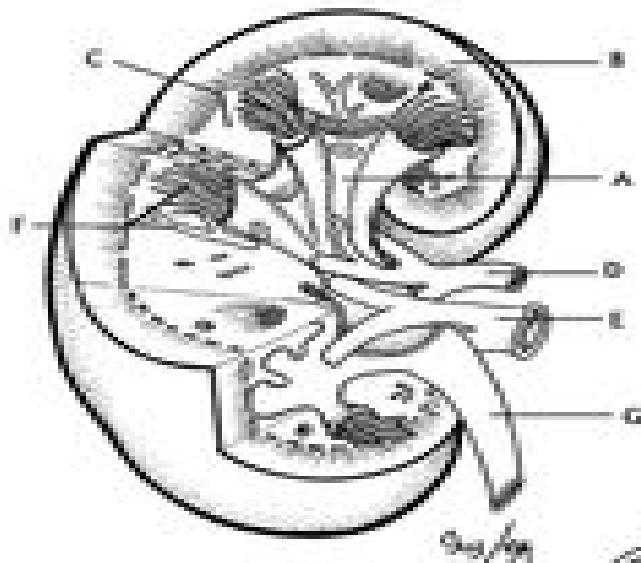


## STRUCTURE OF THE NEPHRON



RENAL PELVIS,  
CORTIX,  
MEDULLA,  
RENAL ARTERY,  
RENAL VEIN,  
NEPHRON,  
URETER.

BOHMAN'S CAPSULE,  
GLOMERULUS,  
DISTAL TUBULE,  
PROXIMAL TUBULE,  
LOOP OF HENLE,  
CAPILLARIES,  
COLLECTING DUCT.

