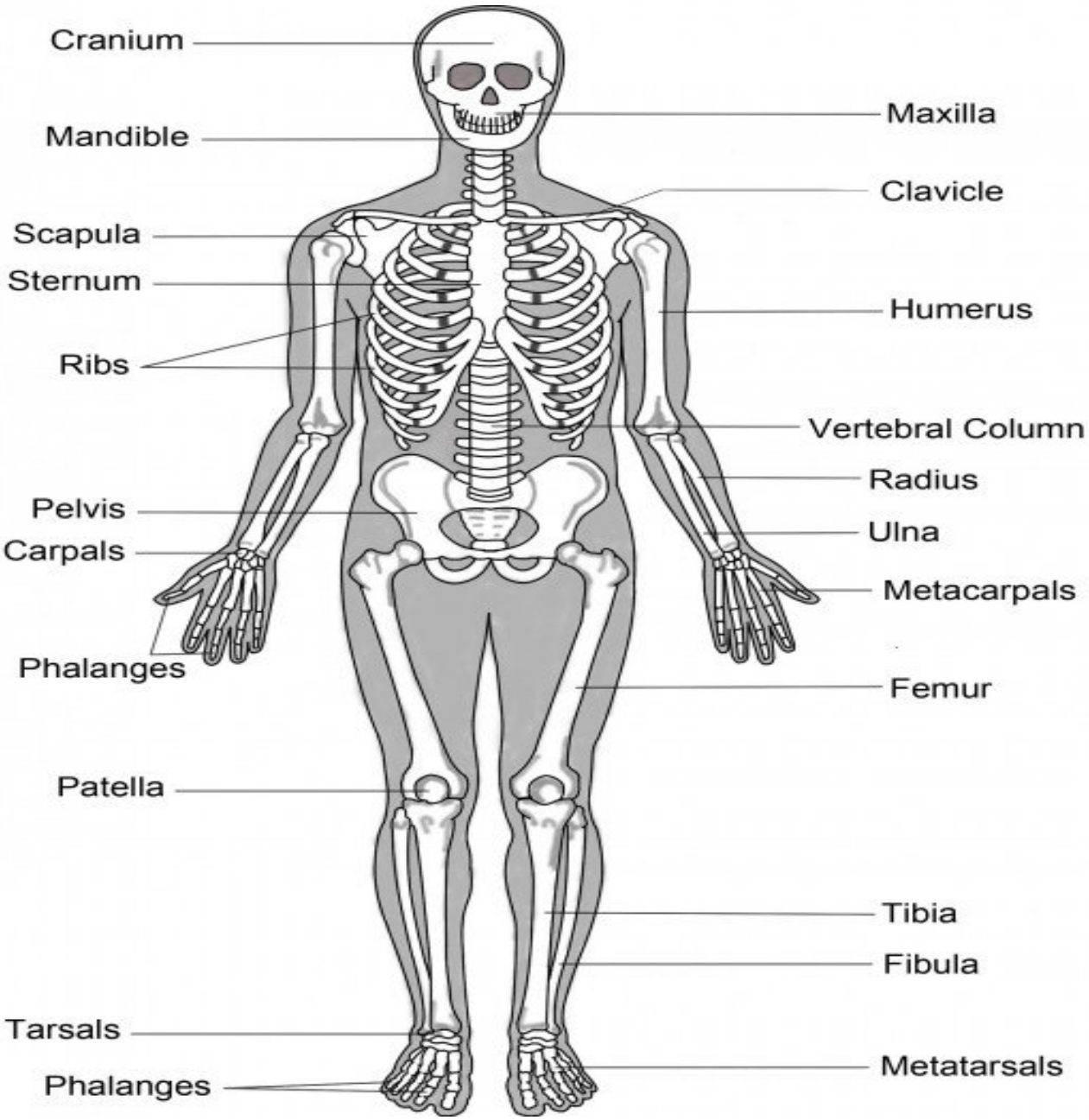
Cranium
Mandible
Scapula
Sternum
Ribs
Pelvis
Carpals
Phalanges
Patella
Tarsals
Phalanges
Maxilla
Clavicle
Humerus
Vertebral Column
Radius
Ulna
Metacarpals
Femur
Tibia
Fibula
Metatarsals