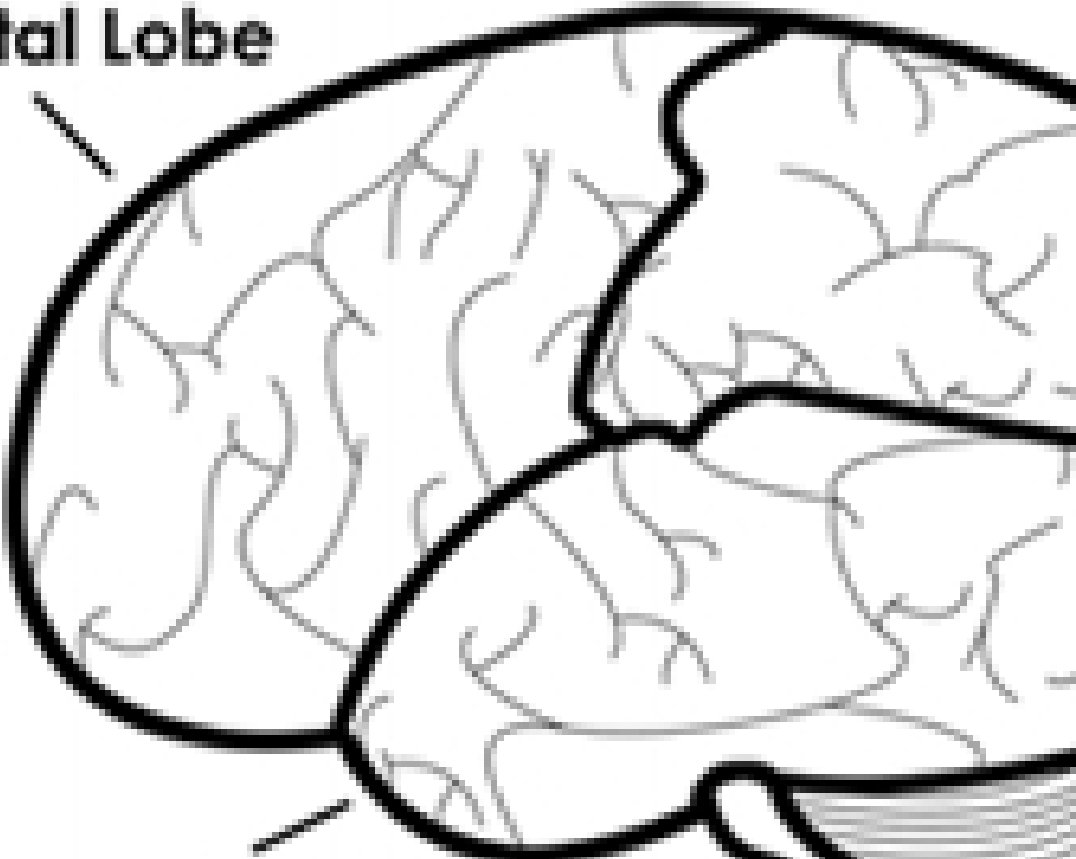


Frontal Lobe



Temporal Lobe

Spinal Cord