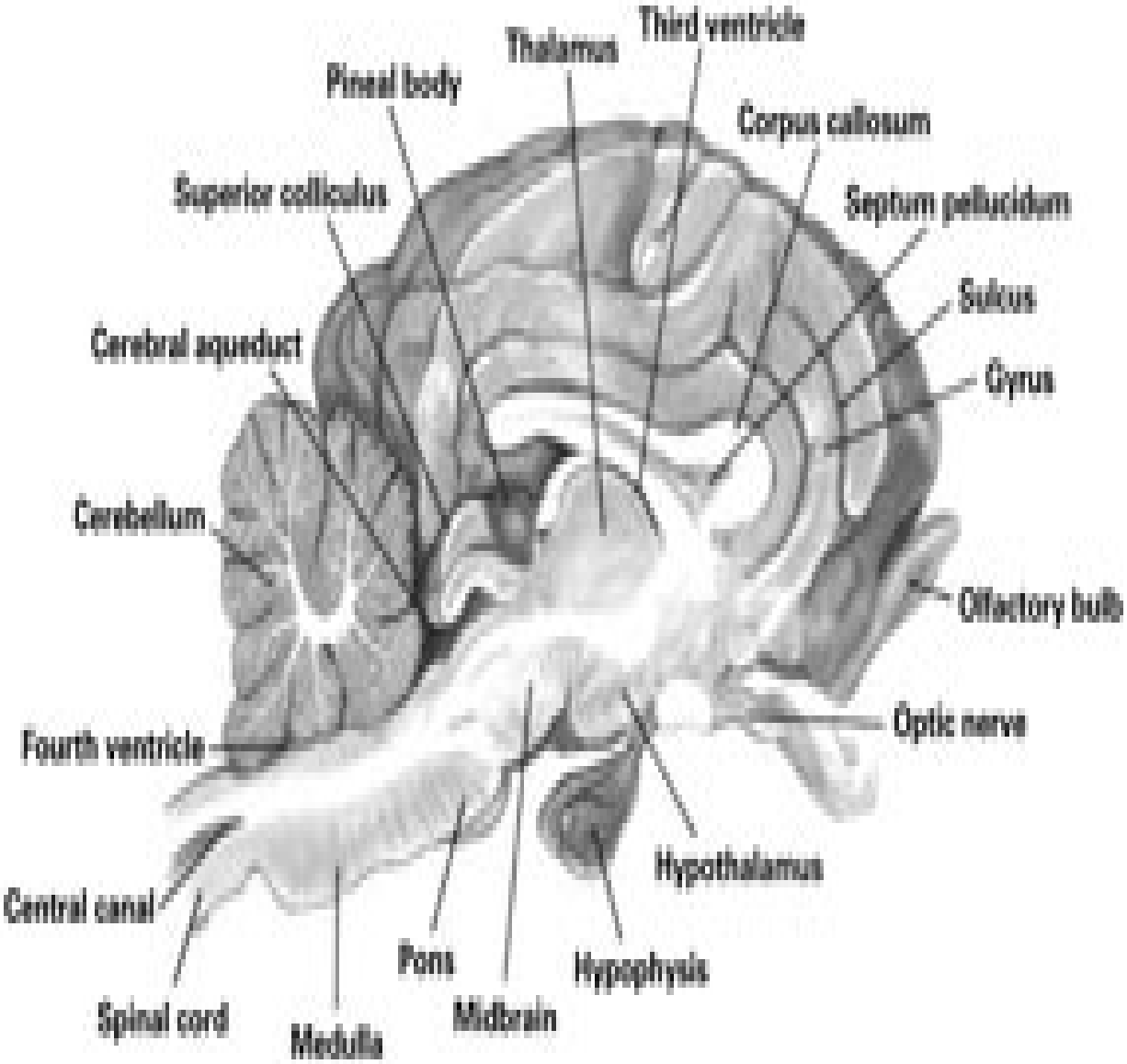
Thalamus
Third ventricle
Pineal body
Corpus callosum
Superior colliculus
Septum pellucidum
Sulcus
Cerebral aqueduct
Gyrus
Cerebellum
Olfactory bulb
Optic nerve
Fourth ventricle
Hypothalamus
Central canal
Pons
Hypophysis
Spinal cord
Medulla
Midbrain