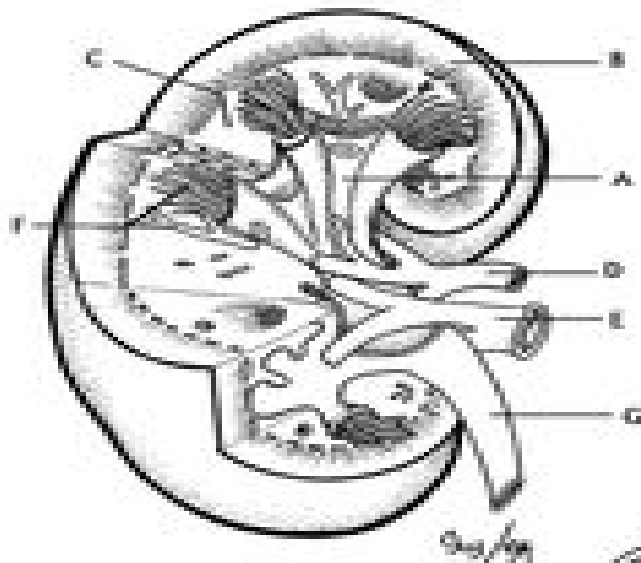


STRUCTURE OF THE NEPHRON



RENAL PELVIS,
CORTIX,
MEDULLA,
RENAL ARTERY,
RENAL VEIN,
NEPHRON,
URETER.

BOWMAN'S CAPSULE,
GLOMERULUS,
DISTAL TUBULE,
PROXIMAL TUBULE,
LOOP OF HENLE,
CAPILLARIES,
COLLECTING DUCT.

