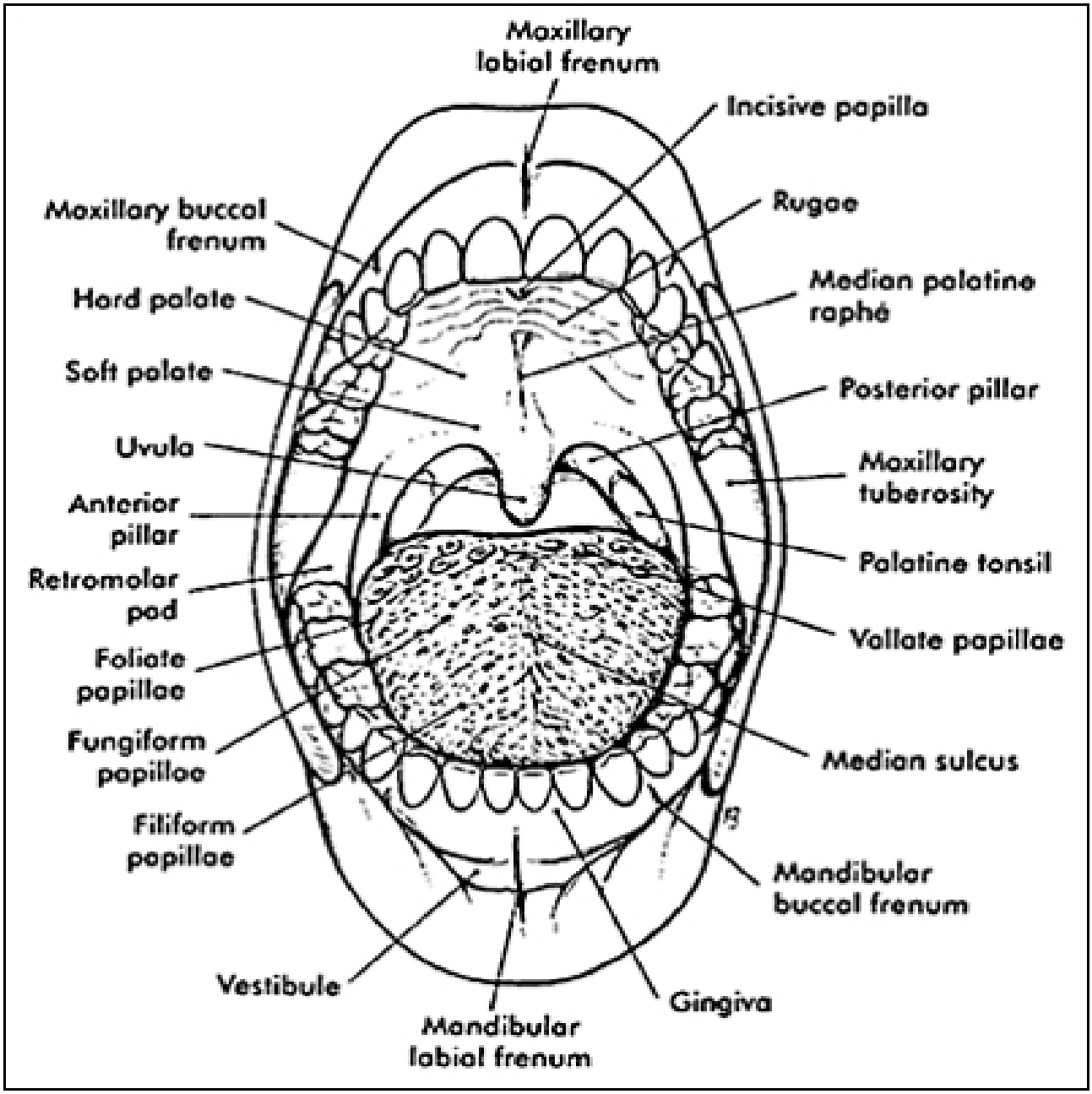
Maxillary labial frenum
Incisive papilla
Maxillary buccal frenum
Rugae
Hard palate
Median palatine raphé
Soft palate
Posterior pillar
Uvula
Maxillary tuberosity
Anterior pillar
Palatine tonsil
Retromolar pad
Vallate papillae
Foliate papillae
Fungiform papillae
Median sulcus
Filiform papillae
Mandibular buccal frenum
Vestibule
Gingiva
Mandibular labial frenum