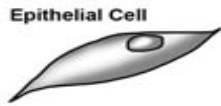
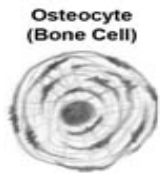


# Organization of the Body


## Cell



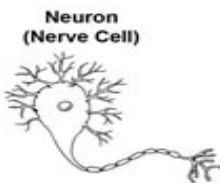
Epithelial Cell



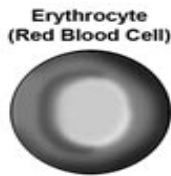
Osteocyte  
(Bone Cell)



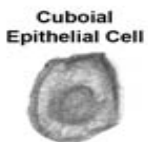
Skeletal Muscle  
Cell



Neuron  
(Nerve Cell)



Erythrocyte  
(Red Blood Cell)

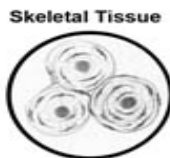

Cuboidal  
Epithelial Cell

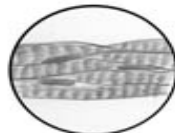
## Tissue



Epithelial  
Tissue



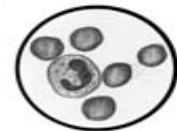
Skeletal Tissue



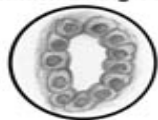Skeletal Muscle Tissue



Nervous Tissue

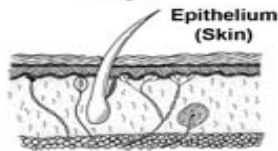


Blood  
(Connective Tissue)

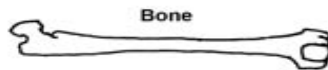


Cuboidal Epithelium  
(Stomach Lining Cell)

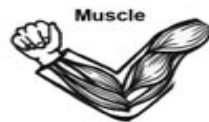## Organ



Epithelium  
(Skin)



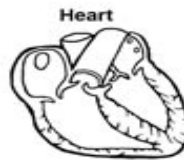Bone



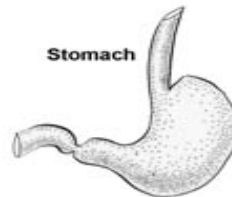
Muscle



Brain



Heart

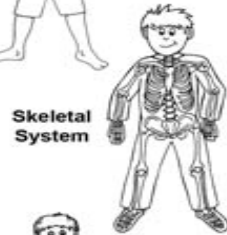


Stomach

## Body System



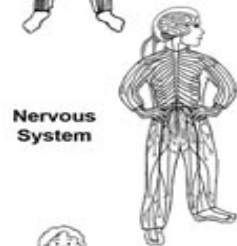
Integumentary  
System



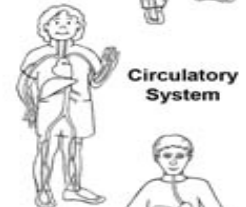
Skeletal  
System



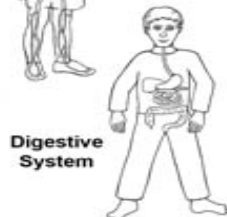Muscular  
System



Nervous  
System



Circulatory  
System



Digestive  
System