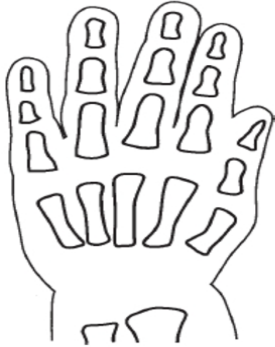

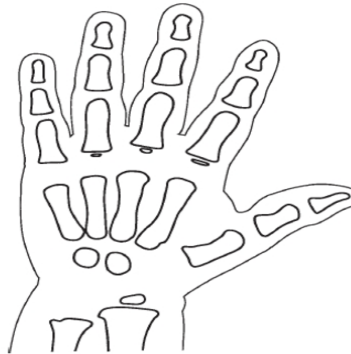THE AGING HAND

Name _____

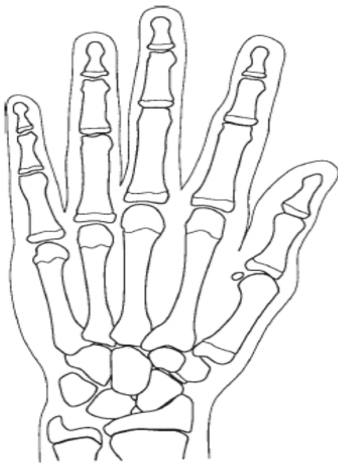
NEWBORN



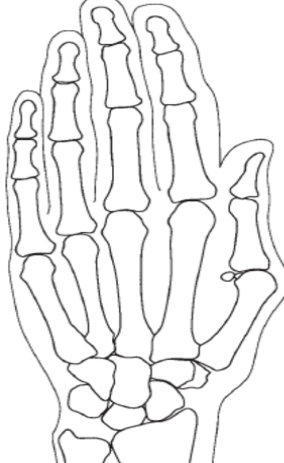1 YEAR



13 YEARS



18 YEARS



1. Color the carpals of all hands blue
2. Color the metacarpals red
3. Color the phalanges dark green
4. Color the radius purple
5. Color the ulna brown
6. Note the bones missing at birth, shade the areas on the newborn pink.
7. Observe the spaces between the bones on the 1 year old – this is the space where the growth plate is found. Shade this area light green.
8. An ossification center (epiphysis) is visible on the 13 year old at the ends of the bone. These are cartilage plates that will turn to bone. Color these yellow on the 13 year old.
9. By 18 years old the ossification centers will fuse with the bone, leaving only the epiphysial line visible. Darken the lines black.
10. Estimate the age of the hand below.

Age = _____

